

Case Report

Pneumonectomy for severe post-tuberculosis bronchiectasis: A successful of case report and review of the long-term outcome

Putri O. Zulfa¹ and Yopie A. Habibie^{2,3*}

¹Medical Research Unit, School of Medicine, Universitas Syiah Kuala, Banda Aceh, Indonesia; ²Division of Thoracic Cardiac and Vascular Surgery, Department of Surgery, Faculty of Medicine, Universitas Syiah Kuala, Banda Aceh, Indonesia; ³Division of Thoracic Cardiac and Vascular Surgery, Department of Surgery, Dr. Zainoel Abidin Hospital, Banda Aceh, Indonesia

*Corresponding author: yopie@usk.ac.id

Abstract

Limited clinical intervention studies highlight the absence of evidence-based international guidelines for effectively managing post-tuberculosis lung disease, emphasizing bronchiectasis. The aim of this study was to describe a case of left pneumonectomy for severe post-tuberculosis cystic bronchiectasis and to provide a review of the post-surgical mortality rate, complications, survival rate, and the patient's quality of life following the pneumonectomy procedure. A 36-year-old Indonesian male smoker presented with worsening breathing difficulties and fever. The patient had a history of pulmonary tuberculosis six years ago and reported negative tuberculosis tests after completing TB treatment. However, lung function of the patient progressively declined over the years. Bronchoscopy, chest X-ray, and high-resolution computerized tomography (CT) scan revealed infected cystic bronchiectasis and identified a prominent left lung collapse with calcification in the left pleura. The patient underwent left pneumonectomy through left posterolateral thoracotomy under general anesthesia. The patient was discharged after seven post-operative days with no eventful course. No further complications were found after a one-year post-surgery follow-up, and the patient returned to normal activities, improved fitness, and was fitter in daily life. Based on the literature review, post-surgical mortality rates of pneumonectomy are acceptable, with bronchopleural fistula, cardiac arrest, and thoracic hemorrhage being common causes. Yet, the chances of a complete cure are high. Complications can occur in approximately one-third of patients, including arrhythmia, pulmonary infection, fever, and wound infections. The overall 5-year survival rate following pneumonectomy is generally favorable. Regarding the quality of life, pneumonectomy can have mixed effects. While it could improve symptoms and quality of life, it may impair the quality of life for certain patients, particularly elderly patients and those with lower preoperative quality of life. Although the post-surgical mortality rate, complications, and long-term survival rates of pneumonectomy are generally satisfactory, the expectation of improved post-surgical quality of life should be discussed with the patient prior to surgery.

Keywords: Pneumonectomy, post-tuberculosis bronchiectasis, tuberculosis, infected bronchiectasis, cystic bronchiectasis



<https://narraj.org/>

Introduction

*T*uberculosis (TB) is remained a significant cause of worldwide morbidity and mortality [1]. According to the WHO Global TB Report 2020, Indonesia had the second highest burden of TB,

with an incidence rate of approximately 354 per 100,000 individuals [2]. A previous history of pulmonary TB is considered a risk factor for long-term respiratory impairment [3]. In countries heavily affected by TB, post-TB is recognized as a primary contributor to the development of bronchiectasis, a consequence of pulmonary TB that can persist or worsen even after completing TB treatment [4,5]. Bronchiectasis management aims to prevent infections and exacerbations [6] and without proper treatment, it can lead to complications such as frequent exacerbations, progressive decline in lung function, and reduced exercise tolerance and quality of life [7-9].

The lack of clinical intervention studies has resulted in the absence of evidence-based international guidelines for managing post-TB lung disease [10]. This poses a challenge for healthcare providers and TB patients who continue to experience persistent and debilitating respiratory symptoms despite achieving a mycobacteriological cure [11]. Conservative treatment is typically adequate for most bronchiectasis patients, while surgical treatment is reserved for focal disease or when medical treatment is no longer viable [12]. Pneumonectomy, the complete lung removal, is a surgical procedure to achieve complete anatomical resection while preserving maximum lung function to prevent cardiorespiratory limitations [13]. The objective of this study was to present a case of left pneumonectomy for severe post-TB cystic bronchiectasis and to provide a brief review of the post-surgical mortality rate, complication, survival rate, and the patient's quality of life following the pneumonectomy procedure. This case report was prepared following the CARE Guidelines [14].

Case

A 36-year-old Indonesian male presented to Dr. Zainoel Abidin Hospital, Banda Aceh, Indonesia with breathing difficulties and fever over the past seven days, leading to hospital admission. The patient exhibited symptoms such as wheezing, wet rhonchi in the left lung, chest pain associated with cough, dyspnea, productive yellowish cough sputum, and lower extremities edema. The vital signs showed blood pressure 123/90 mmHg and with temperature of 36.5°C. The patient had no comorbidities but had a history of pulmonary TB six years ago, which had been successfully treated and reported as mycobacteriological cured. Although the patient had previously been a smoker, he quit after being diagnosed with TB. A few months after completing TB treatment, the patient experienced persistent fatigue, productive cough, dyspnea, breathing difficulties, and hemoptysis. At the time, chest x-ray revealed mild bronchiectasis of the left lung. Over the past five years, the patient had recurrent hospitalizations in the Department of Pulmonology and received long-term medical treatment for recurrent respiratory infections. Despite this, the lung function progressively declined, leading to a referral to the Department of Thoracic Surgery for further treatment.

Bronchoscopy, chest X-ray, and thorax contrast-enhanced computerized tomography scan (CT-scan) were performed. Bronchoscopy confirmed total occlusion of the left main bronchus of the patient. Anteroposterior chest X-ray showed significant radiolucency throughout the left lung (**Figure 1**).

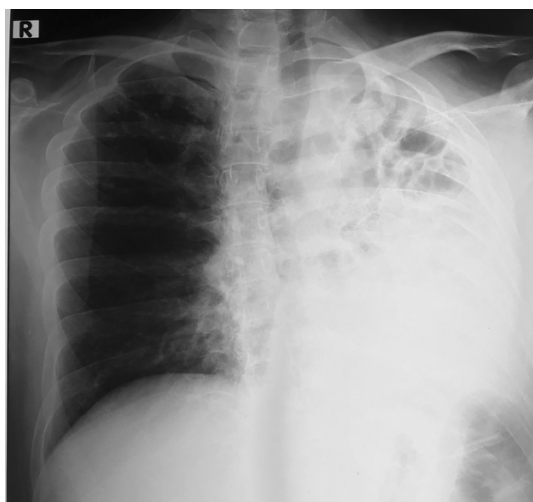


Figure 1. The anteroposterior chest X-ray indicates complete opacity in the left hemithorax.

The thorax contrast-enhanced CT-scan revealed multiple cystic lesions with infiltrates in the left lung, indicating infected cystic bronchiectasis and prominent left lung collapse with left-pleura calcification (**Figure 2**). Based on clinical manifestation, the patient was diagnosed with severe post-TB cystic bronchiectasis of the left lung.

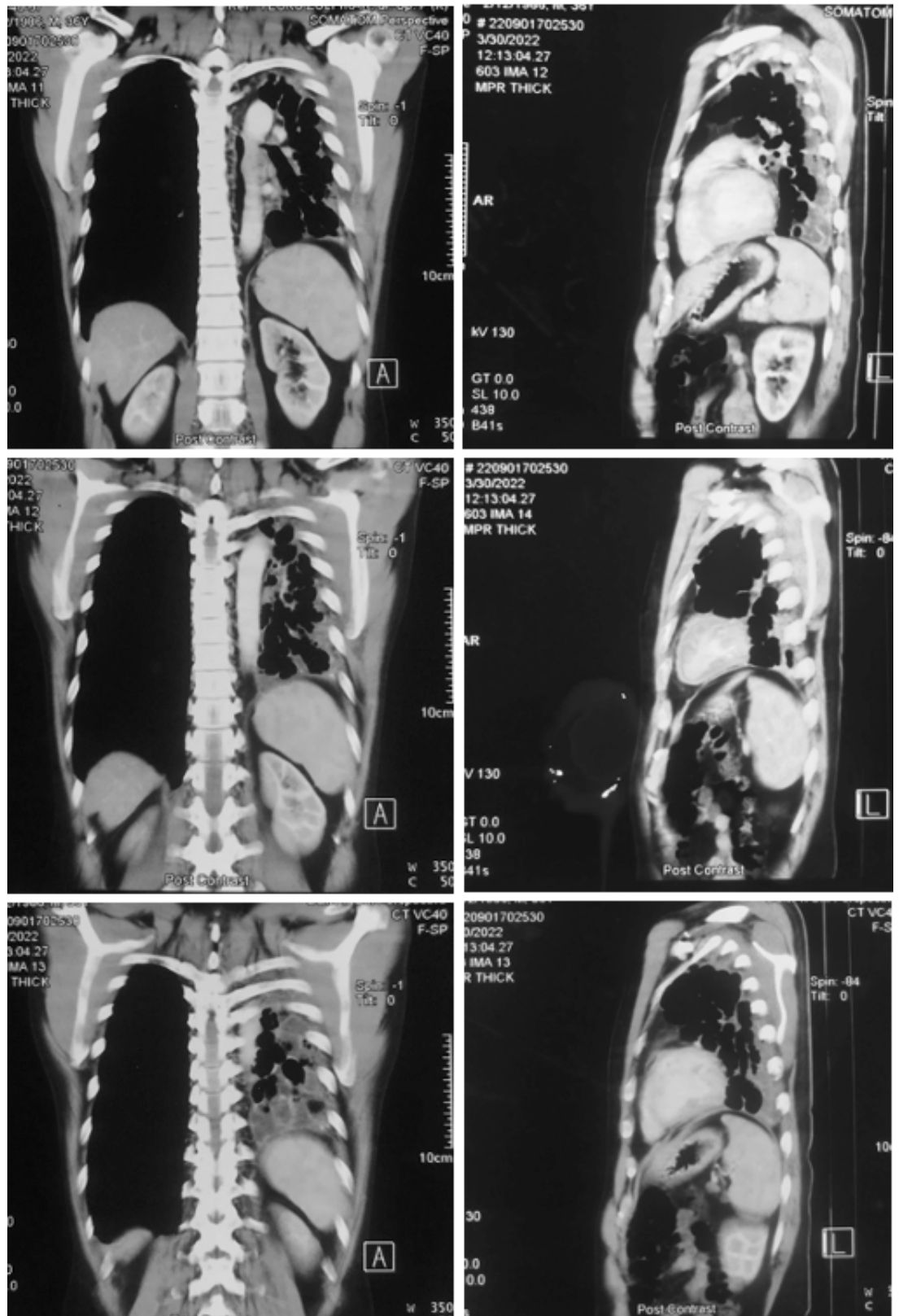


Figure 2. Thorax contrast-enhanced computerized tomography scan (CT-scan) reveals infected bronchiectasis and significant destruction of the left lung, accompanied by left pleural calcification.

Before the surgery, the patient underwent intensive respiratory physiotherapy and microbiological examination of respiratory secretions and received antibiotic prophylaxis. Left pneumonectomy was performed through a left posterolateral thoracotomy under general anesthesia. Adhesiolysis, left pleurectomy, and thrombectomy was carried out. Following the surgical procedures, a left tube thoracostomy was inserted, and the thoracotomy wound was closed in layers. Postoperative care included respiratory physiotherapy and antibiotic therapy. The chest tube output was minimal, and a follow-up chest X-ray demonstrated no signs of fluid accumulation, indicating a lack of collection. Consequently, the chest tube was safely removed.

The prognosis for this patient in terms of survival, functional outcomes, and healing remains uncertain but appears favorable. The patient started the rehabilitation course soon after extubating in ICU. The patient was discharged after seven post-operative days with no eventful course. Monthly follow-up appointments were scheduled at Dr. Zainoel Abidin Hospital for a year. A one-year post-surgical follow-up revealed no further complications. The patient returned to normal activities and experienced improved fitness in his daily life.

Discussion

Our patient had progressive lung deterioration which we presumed was caused by long-term active tobacco consumption. Post-TB lung dysfunction often occurs unrecognized, despite its relatively high prevalence and is associated with reduced quality of life [3]. Reasons for the heterogeneity of pattern and severity of post-TB lung disease are unknown but likely involve host, pathogen, and environmental factors [15]. Tobacco smoking has been shown to positively affect post-TB lung disease in a few studies [16, 17]. Patients with a history of TB and lesions on chest radiographs were associated with 4.47 increased odds of airflow obstruction [18]. While the precise mechanisms are not yet fully understood, there are four important components: (1) the process of granuloma formation and resolution; (2) cytokines production including tumor necrosis factor alpha and interleukins; (3) transcription factors including hypoxia-inducible factor; and (4) enzymes such as the matrix metalloproteinases [15].

Bronchiectasis is a progressive respiratory disease characterized by chronic airway inflammation resulting in irreversibly dilated, thick-walled bronchi and progressive decline in lung function [19]. Criteria for surgery included unsuccessful medical therapy with recurrent respiratory infections, persistent sputum production, chronic cough, persistent lung abscess or hemoptysis, and localized bronchiectasis [12]. Surgical resection is aimed at minimizing the number of resected segments without compromising the disease's elimination objective.

In the present case, the patient had frequent exacerbations as a complication of bronchiectasis. It might be due to recurrent infections, progressively deteriorating lung function, and reduced exercise tolerance and quality of life [20, 21]. This recurring cycle of infection is due to the interplay between structural lung damage, persistent inflammation, viral or bacterial colonization of the respiratory tract, and mucociliary insufficiency [22]. As may it seem in the present case, frequent infectious exacerbations in bronchiectasis patients are associated with higher rates of hospitalization, as well as increase costs for the health system [20, 21, 23].

To the best of our knowledge, limited research is available specifically on the post-surgical mortality rate and pneumonectomy complications solely for post-TB cystic bronchiectasis. However, existing studies have shown that pneumonectomy's mortality rate and complications are comparable to those observed in malignant and non-malignant diseases.

Post-surgical mortality rate and complication

In a recent study, the 30-day and 90-day mortality rates were reported as 3.2% and 6.2%, respectively, with bronchopleural fistula (BPF), cardiac arrest, and thoracic hemorrhage being the leading causes of mortality [24]. Another study reported a perioperative mortality rate of 6.8%, attributed to factors such as intraoperative uncontrolled arrhythmia, postoperative cardiac arrest, and postoperative respiratory failure [25].

In the present case, the patient did not experience any postoperative complications, although it is essential to note that complications may occur in around 36.7% to 39.7% of patients [24, 25]. Several potential complications associated with pneumonectomy should be considered. A study identified postoperative complications such as arrhythmia, transfusion, pulmonary infection,

fever, BPF, and acute respiratory distress syndrome [24]. Another study reported complications, including postpneumonectomy empyema, wound infections, and cases requiring re-exploration due to postoperative bleeding [25].

In the present case, a left pneumonectomy was performed, and we anticipated the possibility of BPF. Fortunately, BPF did not occur in this patient. BPF is a life-threatening complication that can arise after pneumonectomy, although it is less common in left-sided operations due to anatomical differences [25]. The right bronchial stump is more exposed in the pleural space and less likely to be naturally supported by mediastinal tissues than the left one [26].

Survival rate

Despite the challenges, the overall outcome of pneumonectomy is typically favorable, and there is a high likelihood of achieving a complete cure [27]. This is consistent with the patient's experience in the present case, who has survived for a year without encountering any postoperative complications. Survival rates following pneumonectomy for destroyed lungs caused by TB have been reported in previous studies [25,28,29]. A study reported a 5-year survival rate of 88.9% and a 10-year survival rate of 76.2% [25]. Similar result was reported in another study of which a 5-year survival rate of 83% [28]. Kim *et al.* reported that the 5-year and 10-year survival rates of 94% and 88%, respectively [29]. While these studies indicate satisfactory long-term survival rates, the impact of comorbidities on these outcomes needs to be clearly defined, warranting further study.

Quality of life

The patient in the present case experienced an improved quality of life following the surgery. Surgical management of bronchiectasis is highly effective in symptomatic control and subsequently improves the quality of life in patients [12]. However, it should be noted that pneumonectomy may impair the quality of life for some patients, as they may experience symptoms that severely limit their daily activities. A study by Leo *et al* [30] reported that 25% of surviving patients experienced impaired overall quality of life six months after pneumonectomy. Older patients (aged 70 years or older) and those with lower preoperative quality of life were at higher risk of unsatisfactory quality of life after surgery [30]. Therefore, it is essential to routinely discuss recovery aspect with patients prior to performing pneumonectomy.

Conclusion

Patients completing TB treatment should be followed up regularly, particularly if there is evidence of bronchiectasis. Pneumonectomy is recommended when the entire lung is severely damaged and non-functional. While the post-surgical mortality rate, complications, and long-term survival rates of pneumonectomy are generally satisfactory, the expectation of post-surgical quality of life should be discussed with the patient prior to surgery.

Ethics approval

They were not required. The patient provided written informed consent to be published as a case report.

Competing interests

The authors declare that there is no conflict of interest.

Acknowledgments

We would like to express our gratitude to the patient in this study.

Funding

This study received no external funding.

Underlying data

All data underlying the results are available in the article.

How to cite

Zulfa PO and Habibie YA. Pneumonectomy for severe post-tuberculosis bronchiectasis: A successful case report and review of the long-term outcomes. Narra J 2023; 3 (3): e222 - <http://doi.org/10.52225/narra.v3i3.222>.

References

1. Chakaya J, Khan M, Ntoumi F, *et al.* Global Tuberculosis Report 2020 - Reflections on the Global TB burden, treatment and prevention efforts. *Int J Infect Dis* 2021;113:S7-12.
2. World Health Organization. Incidence of tuberculosis (per 100,000 people) - Indonesia data. Global Tuberculosis Report 2020. 2021. Available from: <https://data.worldbank.org/indicator/SH.TBS.INCD?locations=ID>. Accessed: 15 February 2023.
3. Ravimohan S, Kornfeld H, Weissman D, *et al.* Tuberculosis and lung damage: from epidemiology to pathophysiology. *Eur Respir Rev* 2018;27:170077.
4. Chandrasekaran R, mac Aogáin M, Chalmers JD, *et al.* Geographic variation in the aetiology, epidemiology and microbiology of bronchiectasis. *BMC Pulm Med* 2018;18:83.
5. Ko JM, Kim KJ, Park SH, *et al.* Bronchiectasis in active tuberculosis. *Acta radiol* 2013;54:412-417.
6. American Lung Association. Treating and managing bronchiectasis. 2022. Available from: <https://www.lung.org/lung-health-diseases/lung-disease-lookup/bronchiectasis/treating-and-managing>. Accessed: 15 February 2023.
7. Spruit MA. Pulmonary rehabilitation. *Eur Respir Rev* 2014;23:55-63.
8. Spruit MA, Singh SJ, Garvey C, *et al.* An official American Thoracic Society/European Respiratory Society statement: Key concepts and advances in pulmonary rehabilitation. *Am J Respir Crit Care Med* 2013;188:e13-64.
9. Polverino E, Goeminne PC, McDonnell MJ, *et al.* European Respiratory Society guidelines for the management of adult bronchiectasis. *Eur Respir J* 2017;50:1700629.
10. van Kampen SC, Wanner A, Edwards M, *et al.* International research and guidelines on post-tuberculosis chronic lung disorders: a systematic scoping review. *BMJ Glob Health* 2018;3:e000745.
11. Allwood BW, Byrne A, Meghji J, *et al.* Post-tuberculosis lung disease: Clinical review of an under-recognised global challenge. *Respiration* 2021;100:751-63.
12. Coutinho D, Fernandes P, Guerra M, *et al.* Surgical treatment of bronchiectasis: A review of 20 years of experience. *Rev Port Pneumol* 2016;22:82-85.
13. Kosasih KA, Amin Z, Amanda AP. Mortality rate of patients with tuberculosis-destroyed lung who underwent pulmonary resection: Evidence based case report. *Indon J Chest Critical Emergency Med* 2016;3.
14. Gagnier JJ, Kienle G, Altman DG, *et al.* The CARE guidelines: consensus-based clinical case reporting guideline development. *Case Reports*. 2013;2013 oct23 1:bcr2013201554-bcr2013201554.
15. Ravimohan S, Kornfeld H, Weissman D, *et al.* Tuberculosis and lung damage: From epidemiology to pathophysiology. *Eur Respir Rev*. 2018;27:170077.
16. Hnizdo E. Chronic pulmonary function impairment caused by initial and recurrent pulmonary tuberculosis following treatment. *Thorax* 2000;55:32-38.
17. Plit M, Anderson R, Van Rensburg C, *et al.* Influence of antimicrobial chemotherapy on spirometric parameters and pro-inflammatory indices in severe pulmonary tuberculosis. *Eur Respir J* 1998;12:351-366.
18. Choi C-J, Choi W-S, Lee S-Y, *et al.* The definition of past tuberculosis affects the magnitude of association between pulmonary tuberculosis and respiratory dysfunction: Korea National Health and Nutrition Examination Survey, 2008-2012. *J Korean Med Sci* 2017;32:789.
19. Adetiloye A, Erhabor G, Awopeju O, *et al.* Challenges of diagnosing and managing bronchiectasis in resource-limited settings: a case study. *Pan Afr Med J* 2019;32:82.
20. Spruit MA. Pulmonary rehabilitation. *Eur Respir Rev* 2014;23:55-63.
21. Spruit MA, Singh SJ, Garvey C, *et al.* An official American Thoracic Society/European Respiratory Society Statement: Key concepts and advances in pulmonary rehabilitation. *Am J Respir Crit Care Med* 2013;188:e13-64.
22. Hsu D, Irfan M, Jabeen K, *et al.* Post tuberculosis treatment infectious complications. *Inter J Infect Dis* 2020;92:S41-45.

23. Finch S, McDonnell MJ, Abo-Leyah H, *et al.* A Comprehensive analysis of the impact of *Pseudomonas aeruginosa* colonisation on prognosis in adult bronchiectasis. *Ann Am Thorac Soc* 2015; *AnnalsATS*.201506-333OC.
24. Gu C, Wang R, Pan X, *et al.* Comprehensive study of prognostic risk factors of patients underwent pneumonectomy. *J Cancer* 2017;8:2097-2103.
25. Byun CS, Chung KY, Narm KS, *et al.* Early and Long-term Outcomes of Pneumonectomy for Treating Sequelae of Pulmonary Tuberculosis. *Korean J Thorac Cardiovasc Surg* 2012;45:110-115.
26. Darling GE, Abdurahman A, Yi Q-L, *et al.* Risk of a right pneumonectomy: role of bronchopleural fistula. *Ann Thorac Surg* 2005;79:433-437.
27. Al-Ghuzey A, Daffar A, Al-Temimi R, *et al.* A retrospective study of pneumonectomy: Review of 100 cases in Al-Hussein Teaching Hospital/Thi-Qar. *Current Pediatr Res* 2022;:1427-1432.
28. Shiraishi Y, Nakajima Y, Koyama A, *et al.* Morbidity and mortality after 94 extrapleural pneumonectomies for empyema. *Ann Thorac Surg* 2000;70:1202-1206.
29. Kim YT, Kim HK, Sung S-W, *et al.* Long-term outcomes and risk factor analysis after pneumonectomy for active and sequela forms of pulmonary tuberculosis. *Eur J Cardiothorac Surg* 2003;23:833-839.
30. Leo F, Scanagatta P, Vannucci F, *et al.* Impaired quality of life after pneumonectomy: Who is at risk? *J Thorac Cardiovasc Surg* 2010;139:49-52.